Return to Play Following Meniscus Surgery

Alaina M. Brelin, MD*, John-Paul H. Rue, MD

KEYWORDS

• Meniscus • Athlete • Sports • Return to play • Repair • Transplant • Meniscectomy

KEY POINTS

- Meniscectomy offers a faster return to play and is a more attractive option to the in-season athlete.
- Meniscus repair should be performed when possible in the young athletically active patient.
- Accelerated rehabilitation protocols for meniscus repair offer equivalent functional outcomes when compared with traditional regimens.
- Meniscal allograft transplantation is a viable salvage procedure, although return to collision or contact sports must be carefully weighed.

INTRODUCTION

The menisci are semicircular, wedge-shaped cartilages that have been identified to play a role in shock absorption, load bearing, and stabilization of the knee. Over the past few decades, an abundance of research has been dedicated to meniscal preservation procedures, as both cadaveric and clinical studies have demonstrated a risk for early degenerative changes in the knee with complete loss of meniscal tissue (ie, total meniscectomy).[1] The vascular supply to the meniscus has also been extensively researched and demonstrates that the outer peripheral third has adequate blood supply (red-red zone), whereas the inner two-thirds tends be more avascular (red-white zone and white-white zone). This has particular implications on the potential healing of a meniscus repair. Knowledge of the zones of blood supply as well as age of the patient and tear characteristics, such as chronicity, tear pattern, and tear location, can aid in making treatment decisions.[2]

MENISCAL INJURIES IN ATHLETES

Studies have suggested that there is an overall incidence of meniscal tears requiring surgery of 60 to 70 per 100,000 person years and approximately one-third of these tears are sport related.[3] Acute traumatic tears are commonly seen in young athletes

Orthopaedic Surgery Department, Walter Reed National Military Medical Center, 8901 Wisconsin Avenue, Bethesda, MD 20889, USA
* Corresponding author.
E-mail address: abrelin@gmail.com

Clin Sports Med 35 (2016) 669–678
http://dx.doi.org/10.1016/j.csm.2016.05.010 sportsmed.theclinics.com
0278-5919/16/$ – see front matter Published by Elsevier Inc.

Downloaded from ClinicalKey.com at Ohio State University Libraries August 26, 2016.
For personal use only. No other uses without permission. Copyright ©2016. Elsevier Inc. All rights reserved.

who are involved in sports that require cutting or pivoting movements.[2] Managing the athlete with a meniscus tear presents a new level of complexity to orthopedic surgeons. There can be significant pressure from coaches, teammates, and athletes themselves to return to play as soon as possible, as lost hours of play can have substantial cost burdens and deleterious consequences to the career of an athlete. With this in mind, the concept of early functional rehabilitation programs has been implemented to provide a faster return to play while still minimizing the risk for reinjury. Nevertheless, the team physician, coach, athletic trainers, and physical therapists must recognize the at-risk player and ensure that rehabilitation protocols are adjusted on a case-by-case basis. Furthermore, rehabilitation will vary depending on the procedure performed and concomitant injuries identified.[4]

MENISCECTOMY

Meniscectomy can involve partial, subtotal, or total removal of the damaged meniscal tissue and should be used only when a repair is deemed infeasible.[5] Factors such as tear type, location, chronicity, and potential to heal should be taken into consideration along with the patient's age when making treatment decisions. When performing this technique, a minimalistic approach should be used when resecting meniscal tissue and a stable rim should remain with a smooth contoured edge to decrease the risk of recurrent tears. Although patients, specifically athletes, are able to return to physical activities much faster following meniscectomy, the risk of early degenerative changes must not be underestimated. A biomechanical study by Lee and colleagues[6] demonstrated that as the degree of meniscectomy increased, the amount of contact stresses across the tibiofemoral joint significantly increased. It is recommended to conserve as much meniscal tissue as possible and to use meniscal-preserving techniques, such as repair, when feasible, especially in patients with high physical demands. Nevertheless, meniscectomy has the benefit of a faster return to activities and sport.

Rehabilitation following meniscectomy typically involves advancing activities as the patient tolerates them. Most are able to return to running, jumping, and sport-specific training at approximately 6 weeks when knee pain and effusions have subsided and quadriceps/hamstring strength has returned to normal. The speed of this program is due to the lack of a healing meniscus, as the damaged tissue has been removed. The standard protocol at our institution progresses in 3 phases: (1) 0 to 2 weeks: begin weight bearing and range of motion as tolerated along with quadriceps, hamstring, and core strengthening; (2) 2 to 4 weeks: addition of sport-specific exercises and return to cardio training; (3) 4 to 6 weeks: continued advancement in sport-specific training and maintenance of strengthening program. The return of full quadriceps function and strength often can be the most rate-limiting step during recovery, so it is prudent to have early strengthening in an athlete's rehabilitation protocol (**Fig. 1**). An athlete is released to competitive sports once equal strength, full range of motion, and endurance in sport-specific exercises has returned, typically within the 4-week to 6-week time frame.

A review of the recent literature demonstrates only a few studies evaluating the return to play of athletes following meniscectomy. An early study by Osti and colleagues[7] evaluated partial lateral meniscectomy in 41 athletes and found that 98% of patients returned to sport at an average of 55 days. When further divided into subgroups, it was noted that patients with an isolated simple longitudinal tear returned the earliest (average 41 days). Kim and colleagues[8] found a significant difference in time to return to play based on age (<30, 54 days; >30, 89 days) and level of competition (elite, 54 days; competition, 53 days; recreational, 88 days). A more recent article by Nawabi

Downloaded from ClinicalKey.com at Ohio State University Libraries August 26, 2016.
For personal use only. No other uses without permission. Copyright ©2016. Elsevier Inc. All rights reserved.

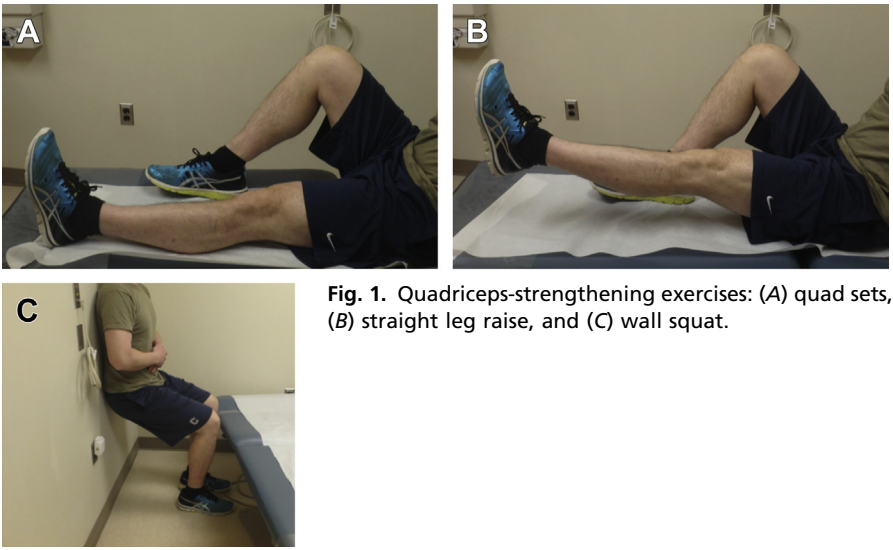

Fig. 1. Quadriceps-strengthening exercises: (*A*) quad sets, (*B*) straight leg raise, and (*C*) wall squat.

and colleagues[9] looking at soccer players undergoing lateral versus medial meniscectomy, identified a shorter time to return to play (5 weeks vs 7 weeks) and a 6.31 higher probability of returning to play in patients undergoing medial meniscectomy as compared with lateral at all time points after surgery. Last, Aune and colleagues[10] evaluated 77 National Football League players, of whom 4 players had midseason lateral meniscectomy and were able to return to play at either 19 or 29 days. It was also noted that speed position players, such as running backs, receivers, linebackers, and defensive backs, were 4 times less likely to return to play.

MENISCUS REPAIR

Meniscus repair remains the treatment of choice for unstable tears in the vascular zone.[11] More recently, in young athletically active patients, the indications are often broadened to include repair of tears extending into the avascular zone of the meniscus. The goal of repair is to maintain as much meniscal tissue as possible so as to avoid alterations in the mechanics of the knee joint and early degenerative changes. Multiple techniques exist for meniscus repair to include inside-out, all-inside, outside-in, and open repair. The inside-out technique remains the gold standard and has been used since the 1980s.[11] The primary disadvantage to meniscal preservation techniques is a longer rehabilitation period, thus further delaying the return of an athlete to sport.

Rehabilitation algorithms for meniscal repair primarily focus on limiting early postoperative weight bearing and deep flexion (>90°). There is a paucity of literature validating postoperative rehabilitation programs; and protocols have largely been anecdotal with very slow progressions and return to sport. Recently, more aggressive approaches have been used with good success and put these traditional methods into question.[12–14] Furthermore, biomechanical analyses provide supportive data that the use of an accelerated protocol is not detrimental to the repair.[15–18] Lin and colleagues[15] demonstrated that compression occurs at the repair site of posteromedial tears

Downloaded from ClinicalKey.com at Ohio State University Libraries August 26, 2016.
For personal use only. No other uses without permission. Copyright ©2016. Elsevier Inc. All rights reserved.

with higher flexion angles, thus promoting the use of early, unrestricted range of motion protocols. Additionally, an earlier study showed that partial weight bearing imparted minimal distortion at the repair and advocated for early weight bearing.[16]

Table 1 displays 3 varying accelerated rehabilitation protocols and their outcomes as compared with more restrictive regimens. All demonstrate that accelerated protocols have equivalent functional outcomes. Although earlier accelerated protocol progressions were time-based, Kozlowski and colleagues[19] published a rehabilitation protocol for athletes using a 3-phase progression based on patient abilities. Only the early phase is governed by time so as to protect the repair for the first 6 weeks. Following this, athletes begin a return to sport progression (static, dynamic, and ballistic phases) if they meet specified subjective and objective criteria. The protocol is complete when athletes have full confidence in their knee and once all rehabilitation efforts have been optimized. This algorithm emphasizes the involvement of athletic trainers in the guidance of the rehabilitation and the decision of returning to sport. The protocol used at our institution is displayed in **Box 1**.

Early reports of meniscus repair in athletes proved promising results in this highly active population. DeHaven and colleagues[20] in 1985 reported successful results in 43 of 49 athletes at an average of 5 years by using an open repair technique. Since the advancement of arthroscopic practice, the use of these minimally invasive techniques has largely replaced the historical open methods. **Table 2** provides a comparison of more recent literature on rates and time to return to sport in the athletic population following meniscal repair. This literature exhibits good rates of return to sport in the athletic population following meniscal repair at approximately 5 to 6 months postoperatively.

MENISCAL TRANSPLANT

Meniscal transplant is often viewed as a salvage procedure when minimal viable meniscal tissue remains within the knee and the risk for arthritis progression is high. Although no absolute indications exist, the ideal patient should have undergone a total or near-total meniscectomy and present with joint line pain, mild chondral changes, normal alignment, and a stable knee.[5] Unfortunately, this patient profile can be seen more often than not in the athletic population, as many athletes will incur the risks of in-season meniscectomy for a faster recovery and return to sport.[27] Regarding meniscal allograft transplantation (MAT), there are varying techniques for implantation to include suturing the meniscal allograft to the meniscal remnant or by inserting the allograft with attached bone blocks at the anterior and posterior attachments.[2] Good outcomes will result from appropriate patient selection, proper surgical technique, and the correct postoperative rehabilitation protocol being used.

Postoperative rehabilitation protocols following MAT are similar to that of a large meniscus repair and require significant time away from high-level activities. Heckmann and colleagues[28] in 2006 described their protocol for meniscal allograft transplants. Weight bearing is restricted until 5 weeks. Range of motion begins at weeks 1 to 2 with 0 to 90° and progresses gradually through week 6. Running, cutting motions, and full sports are not instituted until 7 to 12 months postoperatively. This represents a more conservative protocol, which is less desirable for the career-dependent athlete. More recent literature indicates that athletes are being released to full training exercises as early as 4 months postoperatively.[29] Although this is appealing, the treating physician should have a thorough discussion with the athlete on the risks of returning to high-level activities, especially those who partake in collision or contact sports. The rehabilitation protocol that is used at our institution is outlined in **Box 2**. Our

Downloaded from ClinicalKey.com at Ohio State University Libraries August 26, 2016.
For personal use only. No other uses without permission. Copyright ©2016. Elsevier Inc. All rights reserved.

Table 1
Comparison of accelerated rehabilitation protocols following meniscal repair

Article	Weight-Bearing Status	Range of Motion	Exercises	Sport-Specific Activities	Return to Sport	Outcome
Barber,[12] 1994	As tolerated	As tolerated	As tolerated	As tolerated	As tolerated	Accelerated: 90% success rate (vs 81% success rate in standard); not statistically significant
Shelbourne et al,[13] 1996	0–2 wk: as tolerated	0–2 wk: as tolerated	2–4 wk: closed chain resistance, bike, swim	4–8 wk	FROM, operated leg at 75% strength of nonoperated leg	Accelerated: 90% success rate (vs 88% success rate in standard); not statistically significant
Lind et al,[14] 2013	0–2 wk: TTWB 3–4 wk: FWB	0–2 wk: 0–90 3–4 wk: FROM	8 wk: running	No comment	4 mo	Accelerated: 72% success rate (vs 64% success rate in standard); not statistically significant

Abbreviations: FROM, full range of motion; FWB, full weight bear; TTWB, toe touch weight bear.

Downloaded from ClinicalKey.com at Ohio State University Libraries August 26, 2016.
For personal use only. No other uses without permission. Copyright ©2016. Elsevier Inc. All rights reserved.

Box 1
Rehabilitation protocol following meniscus repair

Phase I: 0 to 2 Weeks

- Full wight bearing (WB) in extension
- ± Brace
- Range of motion (ROM) 0 to 90 while non-WB (NWB)
- Isometric quadriceps strengthening

Phase II: 2 to 6 Weeks

- Full WB in extension
- Continue ROM 0 to 90 while NWB
- Add closed chain exercises, terminal knee extensions

Phase III: 6 to 12 Weeks

- Full WB
- Discontinue brace, if using
- Progress to full ROM
- Begin hamstring and proprioception exercises
- Leg press 0 to 90
- Add stationary bike

Phase IV: 12 to 20 Weeks

- Progress with exercises and activities
- Swim at 12 weeks
- At 16 weeks begin sport specifics and run/jump protocol

athletes are released to sport specifics at approximately 5 months postoperatively under the guidance of the surgeon, athletic trainer, and coaches. Again, it is emphasized by the treating surgeon that returning to sports can have detrimental effects on the outcome and success of this procedure and, therefore, it is highly recommended to refrain from collision or contact sports.

Although evidence suggests that MAT is effective in relieving pain related to the loss of meniscal tissue, there are limited data on return to sport following this procedure.[27] Noyes and colleagues[30] in 2004 assessed the outcomes of meniscal transplantation in 38 patients younger than 50. Although not specifically evaluating "the athlete," they did identify that 31 of 38 patients were unable to participate in sports activities preoperatively, but at final follow-up (40 months) 29 of 38 patients had returned to higher-level activities to include swimming, biking, running, jumping, pivoting, and cutting. Of note, these patients were not released to light recreational sports until 12 months postoperatively, thus demonstrating a very conservative approach to rehabilitation. A 2010 study by Alentorn-Geli and colleagues[31] reported on 15 soccer players undergoing MAT and followed for an average of 36 months. Of the 14 patients available for follow-up, 12 had returned to play soccer at a mean of 7.6 months. They did not comment on their postoperative rehabilitation protocol. Last, Chalmers and colleagues,[29] in 2013, evaluated 13 athletes who were followed for a mean of 3.3 years after a meniscal allograft transplant. Of these, 10 returned to their previous sport, 9 of whom returned at their desired level of play. Patients were released to full training

Downloaded from ClinicalKey.com at Ohio State University Libraries August 26, 2016.
For personal use only. No other uses without permission. Copyright ©2016. Elsevier Inc. All rights reserved.

Table 2
Comparison of return to sport following meniscal repair in athletes

Author	Number of Patients	Technique	Average Follow-Up	Return to Sport	Average Time to Return to Sport	Average Tegner Score Postoperatively
Mintzer et al,[21] 1998	26 patients (29 repairs); 15 had concomitant ACLR	25 inside out; 4 all inside	5 y	92% returned to sport at preinjury level of activity	Not reported	Not reported
Stein et al,[22] 2009	15 patients	Inside out	2.5 y	Not reported	Not reported	5.9 (vs 6.3 preinjury, not significantly different)
Logan et al,[23] 2009	42 patients (45 repairs); 83.3% of repairs had concomitant ACLR	Inside out	8.5 y	81% returned to preinjury level of activity	11.8 mo for all patients; isolated repair was 5.6 mo	Not reported
Stein et al,[24] 2010	31 patients involved in recreational sports underwent meniscal repair	Inside out	8.8 y	94.4% of repair group returned to their sport at preinjury level	Not reported	5.46 (vs 5.50 preinjury, not statistically significant)
Vanderhave et al,[25] 2011	45 patients (49 knees); 14 patients isolated meniscus repair; 31 underwent concomitant ACLR	Inside out	27 mo	89% returned to preinjury level of activity; 100% of patients undergoing isolated repair (14) returned to full sports	6.5 mo for all patients; isolated repair (n = 14) was 5.56 mo	8 (range 6–9); isolated meniscus repair was 8
Hirtler et al,[26] 2015	37 patients	All inside	24.7 wk	All athletes returned to their sport at preinjury level	27 wk	Not reported

Abbreviations: ACLR, anterior cruciate ligament reconstruction.

Downloaded from ClinicalKey.com at Ohio State University Libraries August 26, 2016.
For personal use only. No other uses without permission. Copyright ©2016. Elsevier Inc. All rights reserved.

Box 2
Rehabilitation protocol following meniscus transplantation

Phase I: 0 to 2 Weeks

- Toe Touch WB brace locked in extension
- ROM 0 to 90 without brace and NWB
- Isometric quadriceps strengthening

Phase II: 2 to 8 Weeks

- 50% WB (weeks 2–4)
- Progress to full WB at 4 weeks
- Brace unlocked 0 to 90 (weeks 2–6)
- ROM 0 to 90 when NWB
- Add closed chain exercises, terminal knee extensions
- All activities with brace; discontinue brace at 6 weeks

Phase III: 8 to 12 Weeks

- Full WB without brace
- Progress to full ROM
- Begin hamstring and proprioception exercises
- Leg press 0 to 90
- Add stationary bike

Phase IV: 12 to 20 Weeks

- Progress with exercises and activities
- Swim at 12 weeks
- Add elliptical

Phase V: More Than 20 Weeks

- Advance to sport-specific activities
- At 16 weeks begin run/jump protocol

at 4 months, but it is noted that the average time to return to their previous athletic level was 16.5 months. Overall, this literature demonstrates acceptable results of MAT in the athletic population.

SUMMARY

In conclusion, athletes are a high-demand population, and when treating a meniscal injury, physicians must recognize how surgical decision making and postoperative rehabilitation protocols will affect the athlete's career. Meniscectomy offers a fast return to play with good short-term results, but the long-term risk of osteoarthritis must be weighed when making the appropriate patient selection. Meniscal repair has the benefit of tissue preservation in exchange for a more lengthy rehabilitation, which is less desirable for the in-season athlete. MAT is a sensible option for the athlete with minimal viable meniscal tissue remaining and joint line pain who wishes to maintain an active lifestyle. As the surgeon, one must help the athlete to make a well-informed decision: one that will benefit the athlete's career as well as preserving the health of the athlete's knee.

Downloaded from ClinicalKey.com at Ohio State University Libraries August 26, 2016.
For personal use only. No other uses without permission. Copyright ©2016. Elsevier Inc. All rights reserved.

REFERENCES

1. Belzer JP, Cannon WD Jr. Meniscus tears: treatment in the stable and unstable knee. J Am Acad Orthop Surg 1993;1:41–7.
2. Getgood A, Robertson A. (v) Meniscal tears, repairs and replacement—a current concepts review. J Orthop Trauma 2010;24:121–8.
3. Manson TT, Cosgarea AJ. Meniscal injuries in active patients. Adv Stud Med 2004;4:545–52.
4. Barcia AM, Kozlowski EJ, Tokish JM. Return to sport after meniscal repair. Clin Sports Med 2012;31:155–66.
5. Greis PE, Holmstrom MC, Bardana DD, et al. Meniscal injury: II. Management. J Am Acad Orthop Surg 2002;10:177–87.
6. Lee SJ, Aadalen KJ, Malaviya P, et al. Tibiofemoral contact mechanics after serial medial meniscectomies in the human cadaveric knee. Am J Sports Med 2006;34:1334–44.
7. Osti L, Liu SH, Raskin A, et al. Partial lateral meniscectomy in athletes. Arthroscopy 1994;10:424–30.
8. Kim SG, Nagao M, Kamata K, et al. Return to sport after arthroscopic meniscectomy on stable knees. BMC Sports Sci Med Rehabil 2013;5:23.
9. Nawabi DH, Cro S, Hamid IP, et al. Return to play after lateral meniscectomy compared with medial meniscectomy in elite professional soccer players. Am J Sports Med 2014;42:2193–8.
10. Aune KT, Andrews JR, Dugas JR, et al. Return to play after partial lateral meniscectomy in National Football League athletes. Am J Sports Med 2014;42:1865–72.
11. Giuliani JR, Burns TC, Svoboda SJ, et al. Treatment of meniscal injuries in young athletes. J Knee Surg 2011;24:93–100.
12. Barber FA. Accelerated rehabilitation for meniscus repairs. Arthroscopy 1994;10:206–10.
13. Shelbourne KD, Patel DV, Adsit WS, et al. Rehabilitation after meniscal repair. Clin Sports Med 1996;15:595–612.
14. Lind M, Nielsen T, Faunø P, et al. Free rehabilitation is safe after isolated meniscus repair: a prospective randomized trial comparing free with restricted rehabilitation regimens. Am J Sports Med 2013;41:2753–8.
15. Lin DL, Ruh SS, Jones HL, et al. Does high knee flexion cause separation of meniscal repairs? Am J Sports Med 2013;41:2143–50.
16. Ganley T, Arnold C, McKernan D, et al. The impact of loading on deformation about posteromedial meniscal tears. Orthopedics 2000;23:597–601.
17. Brucker PU, Favre P, Puskas GJ, et al. Tensile and shear loading stability of all-inside meniscal repairs: an in vitro biomechanical evaluation. Am J Sports Med 2010;38:1838–44.
18. Becker R, Brettschneider O, Gröbel KH, et al. Distraction forces on repaired bucket-handle lesions in the medial meniscus. Am J Sports Med 2006;34:1941–7.
19. Kozlowski EJ, Barcia AM, Tokish JM. Meniscus repair: the role of accelerated rehabilitation in return to sport. Sports Med Arthrosc 2012;20:121–6.
20. DeHaven KE. Meniscus repair in the athlete. Clin Orthop Relat Res 1985;(198):31–5.
21. Mintzer CM, Richmond JC, Taylor J. Meniscal repair in the young athlete. Am J Sports Med 1998;26:630–3.

Downloaded from ClinicalKey.com at Ohio State University Libraries August 26, 2016.
For personal use only. No other uses without permission. Copyright ©2016. Elsevier Inc. All rights reserved.

22. Stein T, Mehling AP, Jost K, et al. Measurements of the quadriceps femoris function after meniscus refixation at the stable athlete's knee. Arch Orthop Trauma Surg 2009;129:1063–9.
23. Logan M, Watts M, Owen J, et al. Meniscal repair in the elite athlete: results of 45 repairs with a minimum 5-year follow-up. Am J Sports Med 2009;37:1131–4.
24. Stein T, Mehling AP, Welsch F, et al. Long-term outcome after arthroscopic meniscal repair versus arthroscopic partial meniscectomy for traumatic meniscal tears. Am J Sports Med 2010;38:1542–8.
25. Vanderhave KL, Moravek JE Jr, Sekiya JK, et al. Meniscus tears in the young athlete: results of arthroscopic repair. J Pediatr Orthop 2011;31:496–500.
26. Hirtler L, Unger J, Weninger P. Acute and chronic menisco-capsular separation in the young athlete: diagnosis, treatment and results in thirty seven consecutive patients. Int Orthop 2015;39(5):967–74.
27. Görtz S, Williams RJ, Gersoff WK, et al. Osteochondral and meniscal allograft transplantation in the football (soccer) player. Cartilage 2012;3:37S–42S.
28. Heckmann TP, Barber-Westin SD, Noyes FR. Meniscal repair and transplantation: indications, techniques, rehabilitation, and clinical outcome. J Orthop Sports Phys Ther 2006;36:795–814.
29. Chalmers PN, Karas V, Sherman SL, et al. Return to high-level sport after meniscal allograft transplantation. Arthroscopy 2013;29:539–44.
30. Noyes FR, Barber-Westin SD, Rankin M. Meniscal transplantation in symptomatic patients less than fifty years old. J Bone Joint Surg Am 2004;86-A:1392–404.
31. Alentorn-Geli E, Vázquez RS, Díaz PÁ, et al. Arthroscopic meniscal transplants in soccer players: outcomes at 2- to 5-year follow-up. Clin J Sport Med 2010;20:340–3.

Downloaded from ClinicalKey.com at Ohio State University Libraries August 26, 2016.
For personal use only. No other uses without permission. Copyright ©2016. Elsevier Inc. All rights reserved.